CASE REPORT

Rare Case of Extra Hepatic Umbilical Vein Thrombosis with Superimposed Infection.

Rajat Singhal*, Rahul Sharma*, Ashish Mahla, Annu Bhandari***, Mukesh Mittal****, Kuldeep Mehandiratta*****

ABSTRACT

Umbilical vein thrombosis (UVT) is an uncommon entity which is being increasingly recognized in neonates. Iatrogenic causes such as placement of umbilical venous catheters and severe neonatal disease are major risk factors for umbilical vein thrombosis. We present a case of 20 days old infant who presented with a tender knot in the upper abdomen diagnosed as extra hepatic umbilical vein thrombosis on USG and CT. Interestingly the baby didn't have history of umbilical vein catheterization. Baby was admitted and given intravenous antibiotics and later oral antibiotics. Follow-up USG at 2 months showed complete resolution of the thrombosis and abscess with no residual changes.

Clinical features of umbilical vein thrombosis range from asymptomatic course to umbilical vein thrombophlebitis, liver abscess, sepsis, portal vein (PV) thrombosis and their sequelae. Further course of disease is variable with possibility of high perinatal morbidity and fatality.

USG is the investigation of choice to evaluate the thrombus and its extensions as well as response to treatment. Treatment mainly includes antibiotics and thrombolytic if required. Differential diagnosis of this entity includes thrombosed umbilical vein varix.

INTRODUCTION

Thrombosis of the umbilical vessels is a rare event, occurring in 1 in 1500 deliveries[1]. Heifetz[2] reported an incidence of umbilical cord thrombosis of approximately 1 in 1300 deliveries, 1 in 1000 perinatal autopsies, and 1 in 250 high-risk gestations. Fetal outcome is usually poor, especially when the thrombus forms in one or both umbilical arteries. Umbilical vein thrombosis occurs more that of umbilical arteries. Thrombosis of umbilical vein after birth is another rare entity attributed to mainly umbilical venous catheter placement and severe neonatal sickness.

CASE REPORT

A 20 days-old previously healthy male infant presented to our institution with a 5-day history of abdominal distension, a tender "knot" in the upper abdomen and not passing stools since 5 days. The baby was born by caesarean section due to multiple umbilical cord loops around the neck of baby after an uncomplicated full term gestation. At birth umbilical region was normal and umbilical stump was healthy. The immediate perinatal course was uncomplicated, and there was no history of umbilical catheterization, as per the parents. Antenatal USG showed left multi-cystic dysplastic kidney and it was confirmed on postnatal USG.

On arrival is our institution, the patient had a temperature of 37°C (no fever). All other vital signs were normal. Weight of baby was 2.5 kg. On palpation, a painful firm mass was felt in the periumbilical region. Rest of the physical examination findings were normal. Results of laboratory work-up were normal.

The patient underwent USG followed by contrast enhanced CT scan. Grey scale US images through the epigastric region demonstrate expanded tubular extra hepatic umbilical vein in supraumbilical area with heterogeneous content (thrombus within) with no vascularity. Also a breach in the anterior wall with spillage of the content in anterior abdominal wall (potential abscess formation) was seen.

Contrast enhanced CT of the abdomen, and pelvis showed a tubular hypodense area seen in region of extra hepatic umbilical vein with surrounding enhancement(s/o thrombus with early abscess formation). Portal and hepatic veins were normal.

*Senior Resident, **Junior Resident, ***Professor, ****Associate Professor, *****Senior Professor
Department of Radiodiagnosis, SMS Medical College, Jaipur.
Corresponding Author
Dr. Rajat Singhal, Senior Resident, SMS Medical College
145 Milap Nagar, Tonk Road, Jaipur, Rajasthan
E-mail : drrajatsinghal94@gmail.com
Mobile Number: 8619199832

A diagnosis of thrombosed extrahepatic umbilical vein with likely abscess formation was established. The patient was admitted and given intravenous antibiotics and later oral antibiotics. The baby was then discharged on oral antibiotics. Follow-up USG at 2 months showed complete resolution of the thrombosis and abscess with no residual changes. There was no evidence of any collateral formation and portal vein was normal.

DISCUSSION

Umbilical vein thrombosis is an uncommon entity which is being increasingly recognized in neonates. Incidence of in utero umbilical vein thrombosis is approximately 1/1500 neonates, and in 1/250 high-risk births[1]. Heifetz (1988)[2] reported a slight male predominance in the occurrence of these events. Umbilical vein thrombosis occurs more commonly than umbilical arteries, however fetal mortality is more with arterial thrombosis.

Schrocksnadel et al[3]. have suggested possible aetiologies of umbilical vein thrombosis including mechanical, vascular, inflammatory, fetal, maternal, and iatrogenic. Umbilical venous catheter placement and severe neonatal sickness are the major risk factors for umbilical and portal vein thrombosis. Larciprete et al[4]. have proposed meconium staining as a possible causative factor in umbilical vessel thrombosis. In our case the baby didn't have any history of umbilical vein catheterisation or any of the above risk factors which makes this case even rare.

Clinical features span from asymptomatic course to umbilical vein thrombophlebitis, liver abscess, sepsis, portal vein (PV) thrombosis[5-7] and their sequelae. Further course of disease is variable with possibility of high perinatal morbidity and fatality. Our baby presented with tender and firm mass in the periumbilical region.

USG is investigation of choice to evaluate the thrombus and its extensions as well as response to treatment. Treatment mainly includes antibiotics and thrombolytic if required.

Another condition which may mimic the umbilical vein thrombosis is thrombosed umbilical vein varix[8]. However, it is very rare and may lead to in utero fetal demise decreasing its presentation in neonates. Umbilical vein varix is focal dilatation of the extra hepatic umbilical vein more than 9 mm or 50% greater than that of the intrahepatic umbilical vein. It is typically diagnosed on routine antenatal US as an extrahepatic hypo or anechoic elongated structure located between the anterior abdominal wall and the inferior edge of the liver, with internal flow at Doppler US.

CONCLUSION

Umbilical vein thrombosis is rare entity which is currently being increasing recognized due to improperly inserted umbilical vein catheterisations. An open eye should be kept for any complications in such a case to prevent the morbidity and mortality to the patient.

I

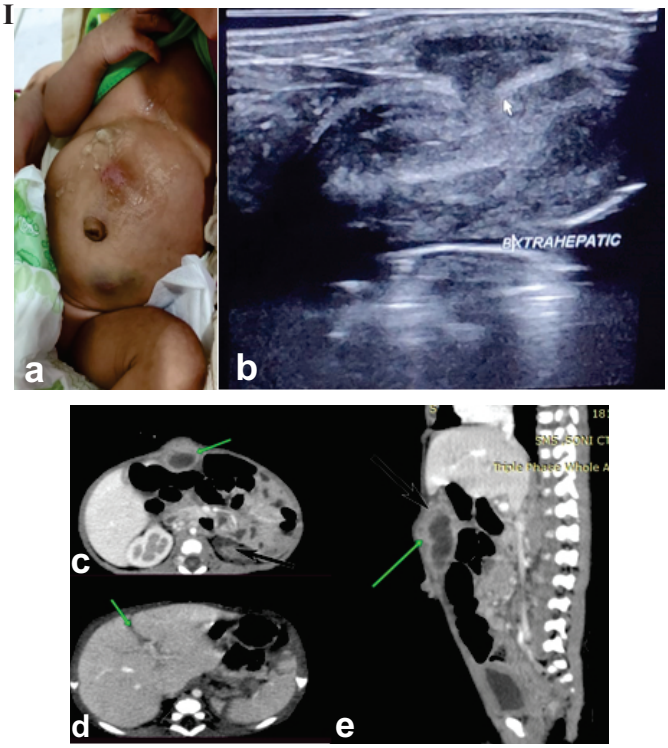

a) 20 days infant showing reddish colour swelling over supraumblical area

b) Grey scale USG demonstrates expanded tubular extrahepatic umbilical vein in supraumblical area with heterogenous content (thrombus within) with no vascularity. White arrow shows breach in the anterior wall with spillage of the content in anterior abdominal wall (potential abscess formation)

c) CECT axial abdomen : Expanded hypodense area seen in region of extrahepatic umbilical vein with surrounding enhancement (s/o thrombus with early abscess formation)

d) CECT abdomen : axial - normal intrahepatic umiblical vein

e) Coronal reformat- same hypodense area(black arrow), green arrow shows site of breech in anterior abdominal wall.

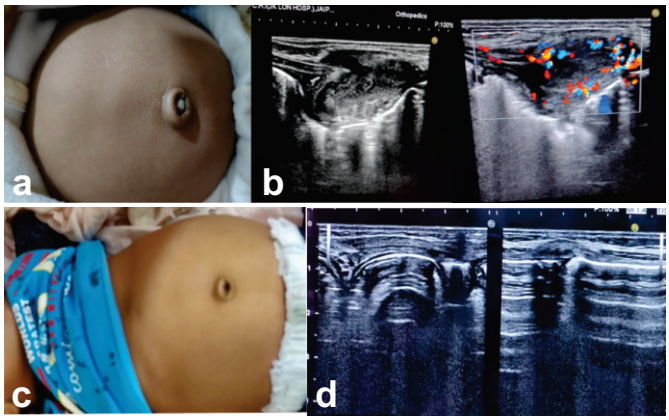

a) Follow up ultrasound 15 days later showing disappearance of reddish swelling over supraumblical area. However pus started coming out of umbilicus.

b) USG (grey scale and colour) shows almost similar size of the lesion. Further follow up at 2 months was advised to see the resolution.

c) Follow up of child at 2 months shows complete resolution of radish swelling and no pus from umbilicus

d) 2 months USG shows no residual thrombus/abscess at the previous site.

REFERENCES

1. Dieminger HJ, Friebel L. Die thrombose der vena umbilicalis [article in German]. Zentralbl Gynakol 1986;108:765–9.
2. Heifetz SA. Thrombosis of umbilical cord: analysis of 52 cases and literature review. Pediatr Pathol 1988;8(1):37–54.
3. Schrocksnadel H, Holbock E, Mitterschiffhaler G, Totsch M, Dapunt O. Thrombotic occlusion of an umbilical vein varix causing fetal death. Arch Gynecol Obstet 1991;248:13–5.
4. Larciprete G, Di Pierro G, Giacomello F, Santacroce C, Valensise H, Arduini D. Absent end diastolic flow in umbilical artery and umbilical cord thrombosis at term of pregnancy. Med Sci Monit 2003;9(5):35–9.
5. Morag I, Epelman M, Daneman A, Moineddin R, Parvez B, Shechter T, et al. Portal vein thrombosis in the neonate: risk factors, course and outcome. J Pediatr 2006;148:735–9.
6. Rubabaza P, Persadie RJ. Two cases of umbilical vein thrombosis, one with associated portal vein thrombosis. J Obstet Gynaecol Can 2008;30(4):338–34
7. Schwartz DS, Gettner PA, Konstantino MM, Bartley CL, Keller MS, EhrenkranzRA, Jacobs HC. Umbilical venous catheterization and the risk of portal vein thrombosis. J Pediatr. 1997;131(5):760.
8. Sandberg JK, Hulett-Bowling R, Khanna G. Case 253:Thrombosed Umbilical Venous Varix in an Infant. Radiology. 2018 May;287(2):719-24.